

Making the Invisible Visible: Near-Infrared Spectroscopy and Phlebotomy in Children

Eugen-Matthias Strehle, M.D.

Northumbria Healthcare NHS Foundation Trust in Association
with Newcastle University, Newcastle upon Tyne, United Kingdom.

Abstract

Aim: Phlebotomy and venous cannulation are the most frequently performed and the most distressing invasive procedures in pediatrics. The aim of this pilot study was to assess whether a novel vein imaging system was advantageous for the identification of superficial veins, thus reducing the number of skin punctures. **Methods:** The Vein Viewer was trialed in 50 children <16 years of age who required venous blood sampling or peripheral venous catheterization as part of their standard clinical care. A questionnaire with 10 questions about their experience of using this equipment was distributed to the pediatric doctors and nurses performing the procedures. **Results:** During a 9-month period, 38 venipunctures and 12 cannulations were performed in 50 children (mean age 6.67 years). On average, 1.7 puncture attempts per child were necessary. Fifty questionnaires were completed by 11 consultants, 16 registrars, 20 senior house officers, and 3 nurses. Seventy-two percent rated the imaging device as useful, 8% as not useful, and 20% remained neutral. Visibility of the peripheral veins was improved in 76% of children, and the same as with room light in 24%. **Conclusions:** Near-infrared technology facilitated venipuncture and venous cannulation in a pediatric cohort. Further, controlled trials are required including children of specific age groups and those from ethnic minorities.

Key words: children, near-infrared spectroscopy, pediatrics, pain, phlebotomy, venipuncture, venous cannulation

Introduction

It is widely accepted among pediatric health professionals that children of all ages are able to feel physical and emotional pain. The Royal College of Nursing and the Association of Paediatric Anaesthetists have published detailed guidelines on how to assess pain in children promptly and how to manage it adequately.^{1,2} Phlebotomy is the commonest invasive procedure carried out in children admitted to a hospital ward or attending a pediatric outpatient department. A recent survey of 37 English children has shown that venipuncture and cannulation are considered extremely distressing, and that currently insufficient measures are undertaken to alleviate this distress.³ Several partially successful techniques have been developed to reduce the painful experience during these procedures and to prevent needle phobia. They include topical anesthetic creams, cooling sprays, and active and passive distraction.⁴⁻⁶ Ultrasonography has been utilized to reduce failure and complication rates in pediatric central venous catheter placement, but its effectiveness has been questioned.⁷ Zeman et al.⁸ have developed a near-infrared imaging system that enhances the visual contrast of peripheral veins, thus facilitating venous access.⁹ The aim of this feasibility study was to determine whether this new vein imaging system could be used in a pediatric population and whether it had any advantages compared with traditional techniques.

Methods

PARTICIPANTS

The study was conducted in the children's outpatient department and in the children's assessment unit of a district general hospital between June 1, 2009, and February 21, 2010. Fifty children under 16 years who required venous blood sampling and/or venous catheterization for routine clinical purposes were enrolled in the study. Suitable peripheral veins in the cubital fossa or on the dorsum of the

STREHLE

hand were identified using a dedicated vein imaging system (Vein Viewer; Luminetx[®], Memphis, TN). The device was operated in accordance with the manufacturer's instructions and calibrated everyday. After verbal consent from the parents, the skin of children over 1 year was anaesthetized with ethyl chloride spray (Cryogesic[®], IS Pharma, Chester, United Kingdom) or a eutectic mixture of lidocaine and prilocaine (EMLA[™] Cream 5%; Astra Zeneca, London, United Kingdom) covered by a sterile polyurethane dressing.^{10,11} In adherence to local guidelines, no topical anesthetic was used for children aged <1 year. A tourniquet was applied to hinder venous blood flow temporarily. Blood was drawn and venous access was obtained according to standard procedures. The project was approved by the local research and development department. Formal ethics approval was not deemed necessary.

The Vein Viewer consists of an apparatus that is attached to an extendable, height-adjustable arm, mounted onto a mobile four-wheel cart, which is connected to a power cable (Fig. 1). The apparatus houses an array of light-emitting diodes that produce near-infrared light at a peak wavelength of 760 nm. The near-infrared radiation is able to penetrate the skin at a right angle up to 10 mm deep from a distance of 61 cm (24 inches). The hemoglobin present in venous blood vessels absorbs light of this wavelength, whereas the surrounding subcutaneous fat tissue reflects it. Adjacent to the light-emitting diode array is an infrared video camera that captures the resulting image, and a video projector that casts the image real-time onto the skin surface. The veins appear as dark lines and the skin fluoresces green (Fig. 2). Near-infrared radiation is not harmful, but staring into the light source has to be avoided.¹²

A 1-page questionnaire was designed containing 10 closed and open-ended questions, which were intended for the health professional performing the procedures outlined above. The questions related to the seniority of the operator, practicalities of using the vein viewer, its effectiveness, and its acceptance among staff and families (see Appendix).¹³

Results

Fifty questionnaires were completed between June 1, 2009, and March 31, 2010: 11 by consultants, 16 by registrars, 20 by senior house officers, and 3 by nurses. They had been taught how to use the Vein Viewer by a colleague (n = 37) or by reading the instruction manual (n = 13). A calibration was carried out once every morning, which lasted <5 min. After that, it took about 1 min to switch on the device. No additional patient preparation was necessary. Of the 50 patients, 38 had blood drawn for diagnostic purposes, and 12 had a cannula inserted for intravenous treatment. The mean age of the



Fig. 1. Mobile vein imaging system.

patients was 6.67 years (80 months, range 1–180 months). On average, 1.7 attempts were made per child before the procedure was successful, ranging from one to seven skin penetrations (85 in total). In the majority of children, the Vein Viewer was used at the outset, but in a small proportion it served as a rescue device after several failed attempts. On one occasion, an anesthetist had to be summoned for assistance, but intraosseous access was never required.

The Vein Viewer projected an approximately 7.0 cm × 5.5 cm green rectangle onto the patient's skin. The light beam could not be adjusted according to the dimensions of the target object. For the image to stay in focus, it was necessary to keep the arm of the child still, which was difficult to achieve in the younger age group. Visibility of the veins was improved in 76% and the same as with natural vision in 24%. The Vein Viewer did not cause any adverse effects and was

ROBOTIC SURGERY, TECHNOLOGY, TELEMEDICINE, TELESURGERY, TELEHEALTH

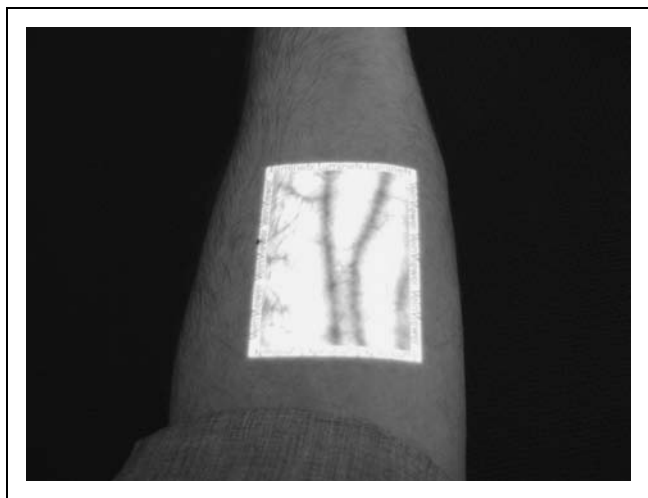


Fig. 2. Left arm of a volunteer depicting two illuminated ante-brachial veins.

acceptable to all patients and parents who welcomed this novel equipment as medical advancement. Overall, 72% of pediatric doctors and nurses considered the device as useful, 8% as not useful, and 20% assumed a neutral attitude toward it (*Table 1*). Seniority did not influence the type of answer given. Medical and nursing staff commented that in some patients it was difficult to judge the depth in which the vein traveled underneath the skin and that palpation of the blood vessel was more important. The relatively large size of the Vein Viewer was considered a disadvantage in a confined space, but the

T1

	USEFUL	NEUTRAL	NOT USEFUL
General effectiveness	36 (72%)	10 (20%)	4 (8%)
	Better	Same	Worse
Visibility of peripheral veins	38 (76%)	12 (24%)	0 (0%)
	High	Medium	Low
Acceptance by families	50 (100%)	0 (0%)	0 (0%)

equipment was thought to be beneficial in dark-skinned children where subcutaneous veins are not easily detectable.

Three different techniques were identified for penetrating the skin with a hypodermic needle or a peripheral venous catheter. (1) The skin overlying the illuminated vein was punctured directly; this sometimes resulted in a distortion of the image due to the pressure applied by the sterile needle or the fingers of the health professional. (2) The fluorescent rectangle showing a suitable vein was approached from an edge where the vein was leaving the near-infrared beam, therefore no blurring of the image occurred. (3) After observing an appropriate vein, it was marked with a skin-marking pen; the device was switched off, and the procedure was performed under normal light.

Discussion

Near-infrared spectroscopy has been used for medical purposes for over 30 years, and it has been particularly valuable for measuring cerebral blood flow and oxygenation in neonates noninvasively.^{14,15} Visible light has a wave length ranging from about 380 to 750 nm, whereas the spectrum from about 750 to 2500 nm is called near-infrared light. When light rays of a defined wavelength hit a flat surface at a 90° angle, they are either reflected or absorbed depending on the physical and chemical properties of the surface. The absorption spectra of water and lipids are very similar, but they differ from the absorption spectrum of hemoglobin. At a wave length between 450 and 1000 nm hemoglobin has a high and water a low absorption (specific extinction coefficient).¹⁶ These properties enable the Vein Viewer to detect hemoglobin-carrying blood vessels that are embedded in subcutaneous fat tissue.

Various research groups have investigated the diagnostic value of near-infrared technology in animal models and in humans. Livingston et al.¹⁷ tested a hand-held optical probe emitting visible and near-infrared light on pigs during gallbladder surgery. They obtained distinct reflectance spectra for porcine gallbladder, portal vein, and artery, which may help to avoid bile duct injury. A Japanese group used two special cameras to capture hyperspectral images from a pig intraoperatively. They were able to produce characteristic radiance data for arteries and veins.¹⁸ Wieringa et al.¹⁹ designed a stereoscopic blood vessel contrast enhancer that allows improved observation of normal and varicose veins through white and darkened skin at a wavelength of 920 nm. Kikuchi and Hosokawa performed fluorescence video venography on 20 patients undergoing saphenous vein surgery. Their method involves intravenous injection of indocyanine green and vein identification with a portable near-infrared imaging device.²⁰ A further development in this field is the creation of

STREHLE

three-dimensional images of subcutaneous veins by combining near-infrared and laser technologies.²¹

One previous study described the application of a prototype vein contrast enhancer system in 146 pediatric subjects and found improved visibility in 84%.⁸ The study presented in this report has demonstrated that a near-infrared imaging system can be used to aid venipuncture and cannulation in children of different ages. The novel device was considered beneficial by a majority of staff and well accepted by patients and parents. Limitations of the study were the relatively small sample size and the lack of a comparison group. Phlebotomy is a complex sensory-motor skill acquired by many pediatric doctors and nurses. It requires good eye-hand coordination and improves with regular practice.^{22–24} The Vein Viewer can assist healthcare workers in training with the localization of peripheral veins. It is likely to increase the first puncture success rate, therefore reducing the amount of pain inflicted on acutely or chronically ill children. The equipment also benefits patients in whom venous access is particularly difficult, for instance, in obese children or those with poor perfusion.

Future research should involve subjects of defined age ranges such as neonates or infants, and pediatric patients with specific conditions, for instance, sickle cell disease or thalassemia. Inclusion of control groups would allow an assessment of the effectiveness of near-infrared technology compared with traditional methods.

Contributors

E.-M.S. designed the study and the questionnaire, arranged the purchase of the equipment from overseas, and wrote the article.

Acknowledgments

The author would like to thank the families and the staff at North Tyneside General Hospital who participated in the study. The Hospital Volunteer Service at Northumbria Healthcare NHS Foundation Trust sponsored the purchase of the Vein Viewer.

Disclosure Statement

I declare that I have no conflicts of interest.

REFERENCES

- Royal College of Nursing—Clinical Practice Guidelines: The Recognition and Assessment of Acute pain in Children. Update of full guideline, September 2009. Available at www.rcn.org.uk/development/practice/clinicalguidelines/pain (last accessed March 23, 2010).
- Association of Paediatric Anaesthetists of Great Britain & Ireland—Good practice in postoperative and procedural pain, June 2009. Available at www.rcpcha.ac.uk/Research/ce/Guidelines-frontpage/Guideline-Appraisals-by-Specialty/Guidelines-of-Interest-to-Paediatrics (last accessed March 23, 2010).
- Hands C, Round J, Thomas J. "When someone stabs you": Children's perspective of venepuncture. *Arch Dis Child* **2009**;94:466.
- Thurgate C, Heppell S. Needle phobia—Changing venepuncture practice in ambulatory care. *Paediatr Nurs* **2005**;17:15–18.
- Murphy G. Distraction techniques for venepuncture: A review. *Paediatr Nurs* **2009**;21:18–20.
- Gilboy S, Hollywood E. Helping to alleviate pain for children having venepuncture. *Paediatr Nurs* **2009**;21:14–19.
- Sigaut S, Skhiri A, Stany I, Golmar J, Nivoche Y, Constant I, Murat I, Dahmani S. Ultrasound guided internal jugular vein access in children and infants: A meta-analysis of published studies. *Paediatr Anaesth* **2009**;19:1199–1206.
- Zeman HD, Lovhoiden G, Vrancken C. The clinical evaluation of vein contrast enhancement. *Conf Proc IEEE Eng Med Biol Soc* **2004**;2:1203–1206.
- Miyake RK, Zeman HD, Duarte FH, Kikuchi R, Ramacciotti E, Lovhoiden G, Vrancken C. Vein imaging: A new method of near infrared imaging, where a processed image is projected onto the skin for the enhancement of vein treatment. *Dermatol Surg* **2006**;32:1031–1038.
- Davies EH, Molloy A. Comparison of ethyl chloride spray with topical anaesthetic in children experiencing venepuncture. *Paediatr Nurs* **2006**;18:39–43.
- Needham R, Strehle EM. Evaluation of dressings used with local anaesthetic cream and for peripheral venous cannulation. *Paediatr Nurs* **2008**;20:34–36.
- Luminetx[®]. *Vein Viewer User Guide*. Memphis, TN: Luminetx[®], **2009**;1–71.
- Abramson JH, Abramson ZH. *Survey Methods in Community Medicine, 5th Edition*. Edinburgh: Churchill Livingstone, **1999**.
- Jöbsis FF. Noninvasive, infrared monitoring of cerebral and myocardial oxygen sufficiency and circulatory parameters. *Science* **1977**;198:1264–1267.
- Wyatt JS, Cope M, Delpy DT, Wray S, Reynolds EO. Quantification of cerebral oxygenation and haemodynamics in sick newborn infants by near infrared spectrophotometry. *Lancet* **1986**;2:1063–1066.
- Williams P, Norris K. *Near-Infrared Technology in the Agricultural and Food Industries, 2nd Edition*. St. Paul, MN: American Association of Cereal Chemists, **2001**.
- Livingston EH, Gulaka P, Kommera S, Wang B, Liu H. *In vivo* spectroscopic characterization of porcine biliary tract tissues: First step in the development of new biliary tract imaging devices. *Ann Biomed Eng* **2009**;37:201–209.
- Akbari H, Kosugi Y, Kojima K, Tanaka N. Blood vessel detection and artery-vein differentiation using hyperspectral imaging. *Conf Proc IEEE Eng Med Biol Soc* **2009**;2009:1461–1464.
- Wieringa FP, Mastik F, Cate FJ, Neumann HA, van der Steen AF. Remote non-invasive imaging of blood vessels: First *in-vivo* results of a new multispectral contrast enhancement technology. *Ann Biomed Eng* **2006**;34:1870–1878.

ROBOTIC SURGERY, TECHNOLOGY, TELEMEDICINE, TELESURGERY, TELEHEALTH

AU1 The address of the corresponding author mismatches with the author affiliation. Please check.

20. Kikuchi M, Hosokawa K. Near-infrared fluorescence venography: A navigation system for varicose surgery. *Dermatol Surg* 2009;35: 1495-1498.

21. Paquit VC, Tobin KW, Price JR, Meriaudeau F. 3D and multispectral imaging for subcutaneous vein detection. *Opt Express* 2009;17: 11360-11365.

22. European Resuscitation Council. *European Paediatric Life Support Course, 2nd Edition*. London: Resuscitation Council (UK), 2006.

23. Willock J, Richardson J, Brazier A, Powell C, Mitchell E. Peripheral venepuncture in infants and children. *Nurs Stand* 2004;18:43-50.

24. Duff AJ. Incorporating psychological approaches into routine paediatric venepuncture. *Arch Dis Child* 2003;88: 931-937.

Address correspondence to:
 Eugen-Matthias Strehle, M.D.
 North Tyneside General Hospital AU1
 North Shields NE29 8NH
 United Kingdom

E-mail: strehle@doctors.org.uk

Received: April 23, 2010

Revised: May 11, 2010

Accepted: May 11, 2010

APPENDIX

Vein Viewer Survey

Thank you for taking the time to complete this survey on the usefulness of the Vein Viewer. The purpose of this noninvasive device is to facilitate venepuncture and cannulation in children.

Please mark/circle your answer:

- You are a **Consultant** Registrar Senior House Officer Nurse
- How did you learn to operate the Vein Viewer?
Lecture Colleague Instruction Manual Trial and Error
- How long did it take you to find and switch on the vein viewer?
Minutes: _____
- What did you use the Vein Viewer for?
Venous blood sampling venous cannulation arterial blood sampling
- What was the age of the patient in whom the Vein Viewer was used?
Weeks: _____ Months: _____ Years: _____
- How many attempts did you require for the procedure? State, if you were unsuccessful.
Without Vein Viewer: _____ with Vein Viewer: _____
- Was the visibility of the blood vessel(s) better with the Vein Viewer?
Much better better same worse much worse
- How acceptable was the Vein Viewer to the parents (and the child)?
Very acceptable acceptable neutral not acceptable
- Overall, how do you rate the usefulness of the vein viewer?
Very useful useful neutral not useful useless
- Do you have any comments/suggestions?
Please leave completed form in the bottom tray. Thank you.